

Hyperbaric Oxygen Therapy (HBOT) and Heel Ulcers

Rena G. Diem, RN, BSN, WCC, CHRN
Life Care Hospitals of Wisconsin, Pewaukee, WI

Hyperbaric oxygen therapy (HBOT) increases the ability of the blood to carry and deliver oxygen to the tissues. Patients receiving HBOT breathe 100% oxygen while under increased atmospheric pressure, much like scuba diving. HBOT is provided in a pressurized (usually cylindrical) chamber that measures approximately 3 feet x 7 feet (or slightly wider) in a 100% oxygen environment. HBOT also may be provided in a room large enough to hold multiple people sitting in chairs; this multiperson chamber is pressurized with room air and each patient breathes 100% oxygen through a hood mask.

The inhaled oxygen is absorbed into the tissues from the super-saturated plasma, greatly increasing the oxygen concentration delivered systemically to the cells throughout the body. The vasoconstrictive effects caused by super-oxygenation help reduce edema, subsequently decreasing tissue pressures and allowing for a freer-flowing blood supply.

HBOT aids in wound healing because it increases capillary production, angiogenesis, and the supply of blood to the ulcer. Increased blood supply provides greater oxygen and nutrients to the wound site. Increased oxygenation can slow or halt infectious disease processes from anaerobes and improve the effectiveness of antibiotics. Bone is not highly vascular, so increasing the blood supply to an ulcer with osteomyelitis is vital.

HBOT has been shown successful in the treatment of heel ulcers with bone infections that fail to heal or recur. The Centers for Medicare and Medicaid Services (CMS) guidelines approve the adjunctive use of HBOT in healing foot and heel ulcers when chronic refractory osteomyelitis is present. This modality is an important part of any wound healing or limb salvage program. ■

Share your Pearls for Practice

If your Pearl is selected for publication, you will receive cash honoraria or a free copy of *Chronic Wound Care IV*.

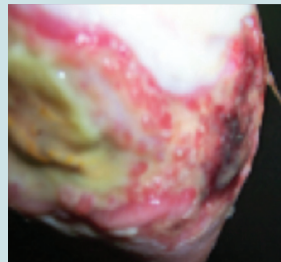
Send your Pearls to the Editor:
bzeiger@hmpcommunications.com.

Commentary By Ferris Mfg. Corp.

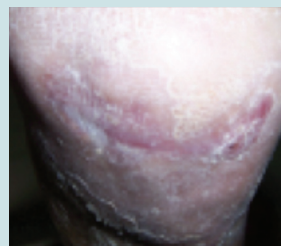Heel ulcers can be painful and difficult to heal. Providing the appropriate care and pain management is essential.

In a representative case study,¹ a 100-year-old female hospice client with a compromised immune system, poor nutrition, and peripheral vascular disease developed a painful blister on her right heel that deteriorated. She had an absent pedal pulse, poor capillary refill, and her right foot was cold to touch. Prior treatment for 10 days included advanced wound care, systemic antibiotics, and floating her heels. The wound was not expected to close.

Drug-free, multifunctional PolyMem Silver® dressings were applied to promote wound healing and facilitate autolytic debridement. PolyMem dressings helped reduce the patient's persistent wound pain and the pain associated with her dressing changes. Because the dressings contain a wound cleanser that continuously cleansed the wound, painful manual wound bed cleansing was unnecessary. The author explained the remarkable healing by noting that the glycerol component in the dressings can be used by the healing tissues as an energy source and as a component in the creation of new cells. ■



May 4: After PolyMem had been applied for 2 weeks. The wound measures 3 cm x 6 cm. Once the wound was granulating and exudate had decreased, PolyMem dressings without silver were initiated.



July 11: The wound closed in 10 weeks.

Reference

1. Yastrub D. Heel Ulcer in Hospice Patient Closed Quickly Using Polymeric Membrane Dressings. Poster presented at the Wound Ostomy Continence Nursing Society's 40th Annual Conference. Orlando, FL. June 21–25, 2008.

Pearls for Practice is made possible through the support of Ferris Mfg. Corp, Burr Ridge, IL (www.polymem.com). The opinions and statements of the clinicians providing Pearls for Practice are specific to the respective authors and are not necessarily those of Ferris Mfg. Corp., OWM, or HMP Communications. This article was not subject to the Ostomy Wound Management peer-review process. This article was not subject to the Ostomy Wound Management peer-review process.