



Ferris Mfg. Corp.

16W300 83rd Street
Burr Ridge, Illinois 60527 USA
Phone: 1-800-POLYMEM, +1 630-887-9797
Email: info@FerrisPolyMem.com
Web site: www.PolyMem.com
www.PolyMem.eu

BIBLIOGRAPHY:

1. Beitz AJ, Newman A, Kahn AR, Ruggles T, Eikmeier L. A polymeric membrane dressing with antinociceptive properties: analysis with a rodent model of stab wound secondary hyperalgesia. *J Pain*. 2004 Feb;5(1):38-47.
2. Fowler E, Papen JC. Clinical evaluation of a polymeric membrane dressing in the treatment of dermal ulcers. *Ostomy/Wound Manage*. 1991;35:35-38,40-44.
3. Sessions RC. Examining the evidence for a drug-free dressing's ability to decrease wound pain. Presented at 23rd Clinical Symposium on Advances in Skin and Wound Care. Poster #136, Oct 27 - 30, 2008. Las Vegas, NV.
4. Kim Y, Lee S, Hong S, Lee H, Kim E. The effects of polymem on the wound healing. *J Korean Soc Plast Reconstr Surg* 1999;109:1165-1172.
5. Burd A, Kwok CH, Hung SC, Chan HS, Gu H, Lam WK, Huang L. A comparative study of the cytotoxicity of silver-based dressings in monolayer cell, tissue explant, and animal models. *Wound Repair and Regeneration* 2007;15:94-104.
6. Clay CS, Chen, WYJ. Wound pain: the need for a more understanding approach. *Journal of Wound Care*. 2005;14:4,181-184.
7. Agathangelou C. Huge Sacral Pressure Ulcer Closed in Four Months Using PolyMem® Silver™ Dressings. Presented at 17th Conference of the European Wound Management Association (EWMA). Poster #135, May 2 - 4, 2007. Glasgow, Scotland.
8. Sibbald RG, Woo K, Ayello EA. Increased bacterial burden and infection: the story of NERDS and STONES. *Adv Skin Wound Care*. 2006 Oct;19(8):447-61; quiz 61-3.
9. Popescu A, Salcido RS. Wound pain: a challenge for the patient and the wound care specialist. *Adv Skin Wound Care*. 2004 Jan-Feb;17(1):14-20; quiz 1-2.
10. Stenius M. Fast healing of pressure ulcers in spinal cord injured (sci) people through the use of Polymem dressings. 10th European Pressure Ulcer Advisory Panel Meeting 2007 August 30 - Sept 1, 2007; Oxford. 2007.

PRESENTED AT :

8th Annual American Professional Wound Care Association. Poster #38. April 2 - 5, 2009 . Philadelphia, PA USA.

PolyMem, PolyMem Silver, PolyMem Wic, PolyMem Wic Silver, PolyMem Wic Silver Rope, PolyMem Max, PolyMem Max Silver, Shapes, Shapes by PolyMem, QuadraFoam, The Shape of Healing, Ferris, and FMC Ferris and design are trademarks of Ferris. The marks may be registered or pending in the US Patent and Trademark Office and in other countries.

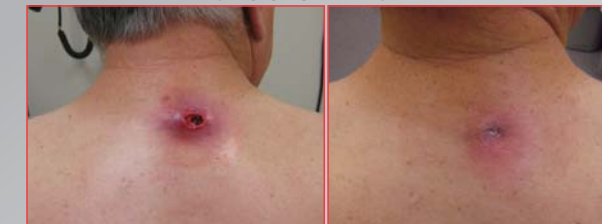© 2009 Ferris Mfg. Corp. All rights reserved.

MKL-409, REV-0, 0709

CASE STUDY

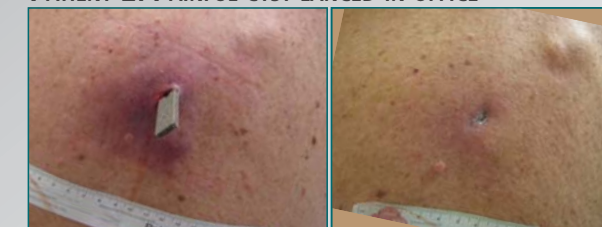Challenges of Dressing Acute Infected Sebaceous Cyst Wounds Met with New Reinforced PolyMem Wic® Silver® Rope Dressing

PATIENT 1: PAINFUL CYST SELF-ERUPTED



PERSISTENT WOUND PAIN DECREASED FROM 6/10 TO 1/10. **CLOSED COMPLETELY IN LESS THAN FOUR WEEKS.**

PATIENT 2: PAINFUL CYST LANCED IN OFFICE



PERSISTENT WOUND PAIN DECREASED FROM 5/10 TO 0/10. **CLOSED COMPLETELY IN LESS THAN FIVE WEEKS**

CASE STUDY

Challenges of Dressing Acute Infected Sebaceous Cyst Wounds Met with New Reinforced PolyMem Wic Silver Rope Dressing

JEREMY TAMIR, MD, FAPWCA, Select Specialty Hospital, Wichita, Kansas, Newton Medical Center, Newton, Kansas and Kansas University Medical School | 611 Birkdale Dr., Wichita, KS 67230 USA

PROBLEM/GOAL

Choosing the proper dressing for painful acute infected wounds can be very challenging. In the first example case study, a 63-year-old male teacher with a history of pheochromocytoma was immunosuppressed due to steroid intake. He developed a large abscess in a sebaceous cyst on his upper back. When he arrived at the clinic two weeks later, the gauze-covered wound had erupted and was self-draining moderate quantities of foul purulent yellow material. The wound margins were necrotic; the periwound skin was macerated, edematous and erythematous. The patient's pain was constant at 6/10; it rose to 7/10 when he was examined. The infected sebaceous cyst on the middle back of the second patient, a 69-year-old diabetic male, was incised and drained in the office. His pain was 5/10 at rest and 7/10 during treatment.

RATIONALE/MATERIALS

Severe pain and tenderness, a small opening and a large, infected, poorly drained, undermined cavity are factors which needed to be addressed. Due to its supporting mesh and small diameter, the new mesh-reinforced PolyMem Wic Silver Rope cavity filler can be easily introduced into a narrow opening, even by family members. PolyMem QuadraFoam dressings can significantly reduce wound pain and they promote the quick formation of healthy granulation tissue. These flexible non-adherent dressings donate or absorb fluid to provide optimal wound bed moisture and continuously cleanse wounds, and the silver versions kill bacteria.

OBJECTIVES

1. Outline the difficulties common to dressing acute infected wounds with small openings and large undermined cavities.
2. List the advantages of using the new mesh-reinforced PolyMem Wic Silver Rope cavity filler, which is very easy to insert and remove, to dress these wounds.
3. Recognize that PolyMem QuadraFoam dressings directly address wound pain and wound cleansing: two problems which are often particularly challenging in acute infected cavity wounds.

METHODOLOGY

Both of these cavity wounds were flushed thoroughly with saline to remove all of the pus and sebaceous material. The necrotic edges of the first patient's wound were surgically debrided; the resultant 1.0 cm x 1.0 cm wound was 15% eschar, 40% slough, 45% avascular tissue with undermining of 4.0 cm from 8 o'clock to 3 o'clock. The second patient's 1.0 cm x 1.0 cm x 3.0 cm wound was 50% fibrin/slough, 50% avascular tissue with 3.0 cm of circumferential undermining. PolyMem Wic Silver Rope cavity filler was inserted into the large areas of undermining in both wounds and the excess material was cut off. Family members replaced the PolyMem Wic Silver Rope cavity filler every day after the patients' showers, without any additional wound cleansing. The first patient also received trimethoprim/sulfamethoxazole tablets for positive staph cultures; the second patient was placed on oral ciprofloxacin.

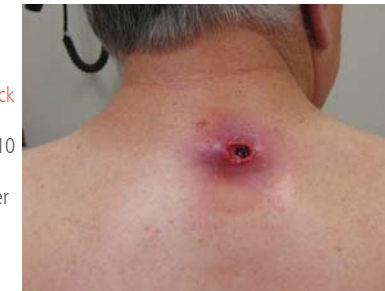RESULTS

The family members had no difficulties atraumatically pulling the spent rope dressing out of the cavities intact. They easily slid a new piece of PolyMem Wic Silver Rope cavity filler into the undermined areas to lightly fill them. At one week, the first patient's wound was 100% granulating with moderate serous exudate, and the undermining had decreased from 4.0 cm to only 1.0 cm. The wound pain had decreased from 6/10 to 1/10 and the periwound was healthy. At the two week followup visit, the wound was only 0.5 cm deep with 0/10 pain. The wound closed completely well before the one-month follow-up visit. The second wound patient fared equally well. Inflammation decreased rapidly; the pain level dropped from 7/10 to 0/10 by the first follow-up visit. The 1.0 cm x 1.0 cm x 3.0 cm deep infected sebaceous cyst wound closed in only one month.

PATIENT 1: A 63-year-old male teacher with immunosuppression from steroid treatment developed a painful (6/10, increasing to 7/10 when touched) sebaceous cyst abscess on his upper back. After suffering with it for two weeks, he came to our clinic. The gauze-covered wound had self-erupted and was draining moderate quantities of thick yellow foul purulent material. The necrotic edges were sharply debrided, the wound was irrigated with normal saline and PolyMem Wic Silver Rope cavity filler was inserted into the wound.

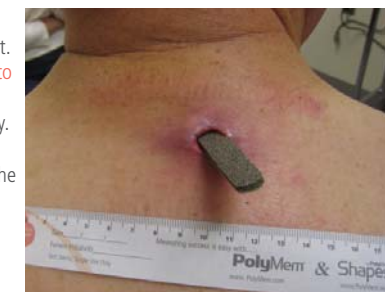Dec 22, 2008

1.0 cm x 1.0 cm x 4.0 cm deep with 4.0 cm undermining from 8 o'clock to 3 o'clock. Persistent wound pain 6/10 with 7/10 treatment pain. PolyMem Wic Silver Rope cavity filler inserted into wound.



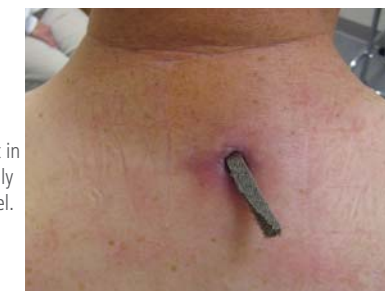Dec 29, 2008

First weekly follow-up visit. Depth already decreased to 1.0 cm, wound fully granulating, edges healthy. Wound pain is only 1/10. Family members change the dressing every 1 – 3 days, after a shower.



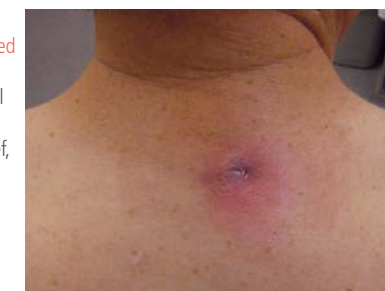JAN 8, 2009

The 0.5 cm deep wound is clean with scant serous drainage. Wound pain is now 0/10. PolyMem Wic Silver Rope cavity filler, cut in half lengthwise, slides easily into the now narrow tunnel.



JAN 22, 2009

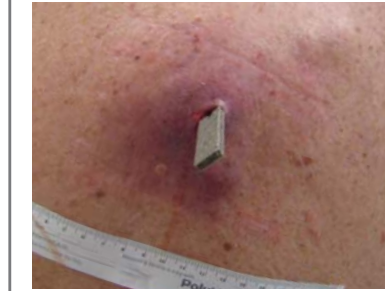
The wound had been closed for some time, but the patient returned for a final photo, impressed with the dramatic wound pain relief, continuous cleansing, and quick granulation tissue formation.



PATIENT 2: A 69-year old diabetic male smoker with hypertension and hypothyroidism had an infected middle-back sebaceous cyst, which he had noticed two weeks earlier, lanced in the clinic, creating a small opening into the deep infected cavity. His wound was irrigated to remove the loose debris and necrotic material. PolyMem Wic Silver Rope cavity filler was inserted into it as well. This patient's persistent wound pain was 5/10, increasing to 7/10 with treatment. Inflammation extended 7.0 cm from the wound site.

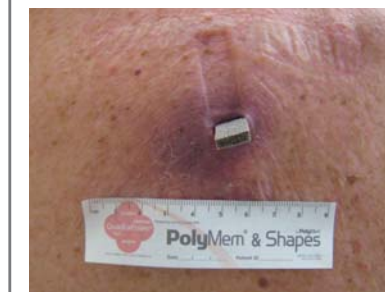JAN 19, 2008

1.0 cm x 1.0 cm x 3.0 cm deep wound with 3.0 cm undermining circumferentially. Persistent wound pain 5/10 with 7/10 treatment pain. PolyMem Wic Silver Rope cavity filler introduced into wound.



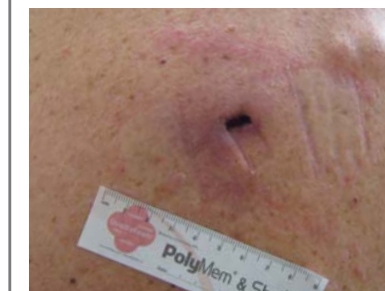JAN 23, 2008

Foul odor gone, cavity depth only 1.0 cm with 0.5 cm undermining. Patient states pain is 0/10 unless someone hits him hard on the back. Wife states dressing is very easy to insert and remove.



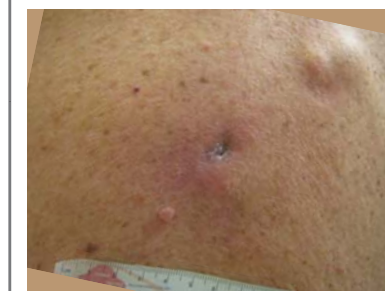FEB 12, 2008

Wound is now only 0.5 cm deep without undermining. No tenderness, no signs of infection. Minimal secretions. Dressing changes are completely atraumatic.



MAR 6, 2008

Patient returned for a final photo. States the wound has been closed for at least 10 – 14 days. PolyMem Wic Silver Rope cavity filler kept his wound clean and pain-free while supporting quick closure.



CONCLUSION

A user-friendly way to support healing in deeply undermined acute infected wounds has long eluded wound specialists. The new PolyMem Wic Silver Rope cavity filler addressed all of the problems of these wounds in these two challenging cases.

This case study was unsponsored. Ferris Mfg. Corp. contributed to this poster presentation.