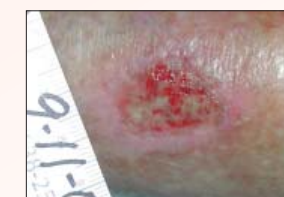
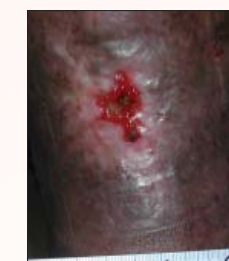
CASE STUDY

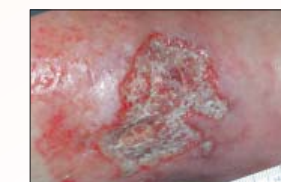Pain Relief and Healing Using PolyMem® and PolyMem Silver® Dressings Under Compression for Venous Hypertension Ulcers



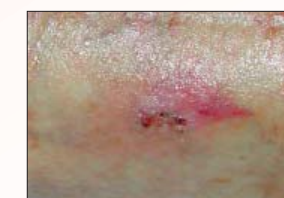TREATMENT INITIATION



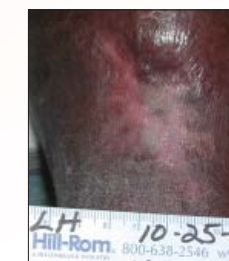TREATMENT INITIATION



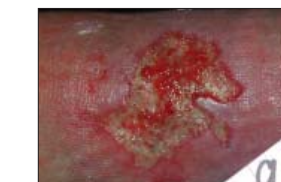TREATMENT INITIATION
CONSTANT PAIN



CLOSED IN 6½ WEEKS



CLOSED IN 6 WEEKS



PAIN FREE IN 9 DAYS



Ferris Mfg. Corp.

16W300 83rd Street
Burr Ridge, Illinois 60527 USA
Phone: 1-800-POLYMEM, +1 630-887-9797
Email: info@FerrisPolyMem.com
Web site: www.PolyMem.com
www.PolyMem.eu

Presented at :

20th Annual Symposium on Advanced Wound Care (SAWC). Poster #160.
April 28 - May 1, 2007. Tampa, FL USA

PolyMem, PolyMem Silver, PolyMem Wic, PolyMem Wic Silver, PolyMem Max, PolyMem Max Silver, Shapes, Shapes by PolyMem, QuadraFoam, The Shape of Healing, Ferris, and FMC Ferris and design are trademarks of Ferris. The marks may be registered or pending in the US Patent and Trademark Office and in other countries. © 2007 Ferris Mfg. Corp. All rights reserved.
MKL-294,REV-0,0308

Pain Relief and Healing Using PolyMem and PolyMem Silver Under Compression for Venous Hypertension Ulcers

PROBLEM

Venous hypertension ulcers greatly decrease the productivity of those who suffer from them. They are often painful, especially during dressing changes, which may be as often as two-to-three times per day. Treatments that decrease overall pain as well as pain during dressing changes can greatly enhance the quality of life for the sufferers of these ulcers. Less frequent dressing changes and, ultimately, wound closure, can result in significant savings of both financial and emotional resources.

This study explores the progression of three patients with painful chronic venous ulcers whose treatment was changed to include PolyMem dressings. When the study began, two of the patients had a single painful ulcer and the third patient had three ulcers.

RATIONALE

PolyMem dressings have a demonstrated ability to reduce wound pain while donating or absorbing moisture as needed. PolyMem dressings also contain ingredients which draw and concentrate the body's natural healing substances into the wound bed, promoting rapid healing. The dressings' built-in gentle cleanser facilitates autolytic debridement directly by loosening the bonds between the slough and the wound bed. The liquefied slough is absorbed by the dressing, so usually no manual wound cleansing is needed, allowing for less disruption of the new growth at the wound bed and very quick and easy dressing changes. In fact, often patients are able to do some of their dressing changes themselves. Therefore, PolyMem dressings were initiated.

PolyMem dressings help inhibit infection. PolyMem Silver dressings have additional anti-infective properties. Therefore, either PolyMem or PolyMem Silver dressings were initiated.

METHODOLOGY

The wound beds were thoroughly cleansed with normal saline and a PolyMem or PolyMem Silver dressing was applied. The dressing was covered with a compression stocking or an Unna's Boot.

Per product instructions, no routine wound cleansing was done on any of the patients during dressing changes, which took place two to four times per week. On some patients, crusts or exudate around the wound area were removed regularly with normal saline. Since manual wound cleansing was not usually indicated, the complex decisions about disturbing new growth versus removing dead tissue were eliminated and two of the patients were routinely able to perform some of their own dressing changes.

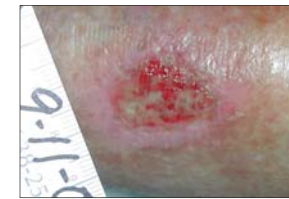
RESULTS

All three patients quickly became pain-free, even during dressing changes. One wound completely closed at 5 weeks, two others closed at 6½ weeks, and the final two were small and superficial at that point but suffered setbacks from lack of adequate compression. Despite this and the patients' serious comorbidities, all of the ulcers were closed by 5 months.

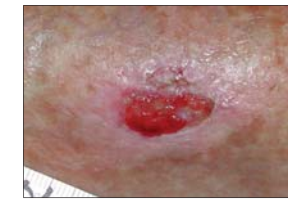CONCLUSION

After only one week of PolyMem dressing use, new granulation tissue was forming in all five of the previously stalled venous hypertension wounds. All three patients quickly became pain-free, even during dressing changes. Three wounds closed by 6½ weeks, and the others closed by 5 months, despite setbacks from failure to wear compression and all of the patients' serious comorbidities. The dressing changes were gentle and very time efficient – just remove the old non-adherent PolyMem dressing and apply a new one.

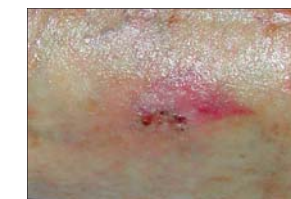Patient 1: An 80-yr-old diabetic woman with a 2.5 cm x 1.6 cm x 0.1 cm deep ulcer for one month. Pain 5 (on 0 –10 scale) during 3x/day treatment with moist saline dressings and long-stretch bandages. No improvement.



September 11
2.5 cm x 1.6 cm x 0.1 cm
70% granulation, 30% fibrin/slough.
Pain 5 during dressing changes.
Initiated use of PolyMem dressings.

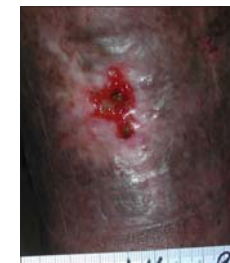

September 27
1.8 cm x 1.0 cm x 0.1 cm
100% granulation tissue. No pain during dressing changes! Wound size decreasing rapidly.

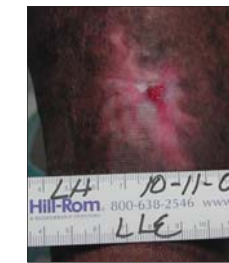

October 25
Dismissed.
Completely closed in only 6½ weeks, despite the patients' advanced age, diabetes and habitual use of caffeine and nicotine.

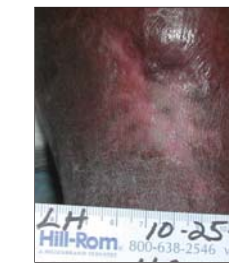Patient 2: A 58-yr-old male bariatric (BMI 55) department store worker frequently missed work due to three large venous ulcers. Pain was a constant 3 and rose to 5 during 7 months of unsuccessful twice-daily treatment prior to use of PolyMem.



September 13
2.5 cm x 2.5 cm x 0.1 cm
Lateral wound: 3 cm x 2.5 cm x 0.1 cm
Posterior wound: 4 cm x 3 cm x 0.5 cm
Initiated use of PolyMem dressings.

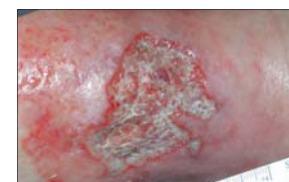

October 11
1.5 cm x 1.3 cm x 0.1 cm
Lateral wound: 3 cm x 2.5 cm
Posterior wound: 3 cm x 3 cm x 0.2 cm
Cleansed the periwound area only.

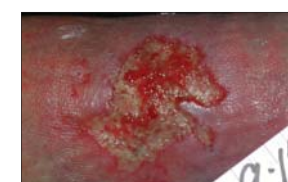

October 25
Fully closed at 6 weeks.
Lateral wound closed October 18.
Posterior wound: 2 cm x 1.5 cm x 0.1 cm
Refused compression but still closed November 29.

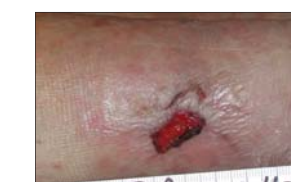Patient 3: An 87-yr-old female with hypertension, hyponatremia, hypothyroidism, osteoporosis, SIADH, GERD and seizures had a painful venous ulcer treated unsuccessfully with wet-to-dry dressings for 2 months.



September 6
3.5 cm x 5.5 cm x 0.3 cm
80% fibrin, 20% granulation.
Constant pain. Using Unna's Boot.
Initiated use of PolyMem dressings.



September 15
3 cm x 4 cm x 0.1 cm
Less edema, 20% fibrin, 80% granulation. No pain, even at dressing changes! Dressing changes only, no wound cleansing.



November 1
1.5 cm x 0.8 cm x 0.1 cm
100% granulation. No pain, but refused Boot. Switched to only compression stockings. Even so, fully closed by February 9 (5 months).

OBJECTIVES

1. Identify PolyMem QuadraFoam as a unique dressing type that promotes appropriate wound moisture conditions and cell proliferation while inhibiting infection.
2. Consider the advantages of using PolyMem dressings in terms of passive continuous cleansing of the wound bed (which usually eliminates painful and time-consuming wound cleansing during dressing changes).
3. Review evidence for the use of PolyMem dressings in the treatment of stalled, chronic wounds.
4. Consider the advantages of using PolyMem dressings in terms of pain reduction.

Mariama Hubbard MSN, APNC, Comprehensive Wound Care Center, Jersey Shore University Medical Center, 1945 State Route 33, Neptune, NJ 07754-0397

This case study was unsponsored. Ferris Mfg. Corp. contributed to the poster presentation.

BIBLIOGRAPHY

1. Fluhr JW, Gloor M, Lehmann L, Lazzerini S, Distanti F, Berardesca E. Glycerol accelerates recovery of barrier function in vivo. *Acta Derm Venereol.* 1999 79: 418-421.
2. Ovington LG. The truth about silver. *Ostomy/Wound Management Supplement.* 2004;50(9A):15-105.
3. Fowler E, Papan JC. Clinical evaluation of a polymeric embrane dressing in the treatment of dermal ulcers. *Ostomy/Wound Manage.* 1991;35:35-38,40-44.
4. Hess CT. *Wound Care Clinical Guide.* Lippincott Williams & Wilkins. Ambler, PA. 2005; 275-276.
5. Baranoski S, Ayello EA. *Wound Care Essentials: Practice Principles.* Lippincott Williams & Wilkins. Ambler, PA. 2004.
6. Kim Y, Lee S, Hong S, Lee H, Kim E. The effects of polymem on the wound healing. *J Korean Soc Plast Reconstr Surg* 1999;109:1165-1172.
7. Beitz AJ, Newman A, Kahn AR, Ruggles T, Eikmeier L. A polymeric membrane dressing with antinociceptive properties: analysis with a rodent model of stab wound secondary hyperalgesia. *J Pain.* 2004 Feb;5(1):38-47.
8. Burd A, Kwok CH, Hung SC, Chan HS, Gu H, Lam WK, Huang L. A comparative study of the cytotoxicity of silver-based dressings in monolayer cell, tissue explant, and animal models. *Wound Repair and Regeneration* 2007 15:94-104.