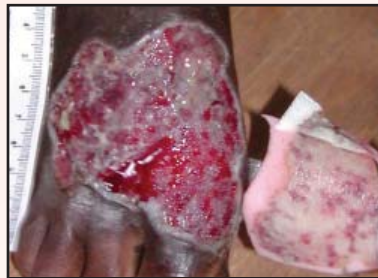
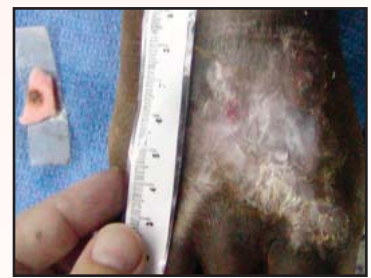
CASE STUDY

Crush Injury Treated with PolyMem Max® Until Complete Wound Closure



BEFORE



AFTER

Crush Injury Treated with PolyMem Max Until Complete Wound Closure

PROBLEM

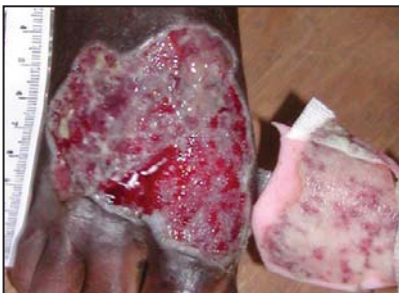A middle-aged woman in northern Ghana, West Africa suffered a large wound when a concrete stone fell, crushing her R foot. Several weeks of treatment with local herbal poultices failed to produce any healing or halt the increasing infection. She arrived at the clinic with an avascular, eschar and slough filled, heavily-exudating 7 cm x 7 cm x 0.3 cm, full-thickness wound, plus acute malaria. The patient's wound pain was constant and severe. She also had chronic severe fungal infections to the plantar aspects of both feet. Since she was from a distant village, she made arrangements to stay in a village only 6 miles from the clinic during her treatment. Grafting was not an option.

RATIONALE

The patient's dressing needed to reduce the pain and be elastic enough to stay in place as she walked the 6 miles to and from the clinic for treatment. Quick healing was especially important because the woman was living away from home during the treatment. This clinician had observed immediate granulation tissue formation in wounds through the use of PolyMem Max dressings in the past. These flexible dressings also have demonstrated ability to reduce wound pain and aid in preventing infection, and they donate moisture to dry wounds while absorbing excess drainage. Therefore, PolyMem Max dressings were initiated.

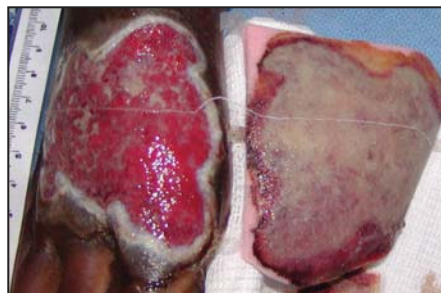
OBJECTIVES

1. Formulate a treatment plan for a large full-thickness wound without the use of grafting.
2. Consider the advantages of using PolyMem Max dressings, which provide passive continuous cleansing of the wound bed; this usually eliminates painful and time-consuming wound cleansing during dressing changes.
3. Consider the advantages in terms of patient confidence and cost of using the same dressing modality from initiation of treatment to closure.
4. Consider the advantages of using PolyMem Max dressings in terms of pain reduction.



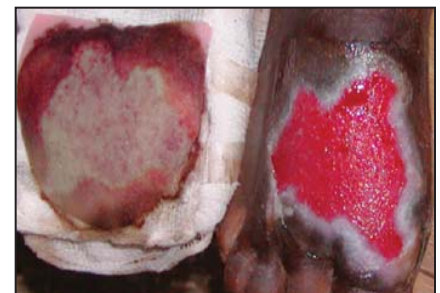OCT 2

7 cm x 7 cm x 0.3 cm
Third day: Light debridement was done to hasten the healing process.



OCT 6

7 cm x 7 cm; only 0.2 cm deep
Seventh day: Manual wound bed cleansing no longer needed at dressing change – granulation is beginning.



OCT 17

6.7 cm x 5.8 cm
Only 1 week later: Wound is filling in quickly, too shallow to measure, and fully granulating.

METHODOLOGY

Treatment included vitamin C supplements plus teaching on nutrition, chloroquine for the malaria, prayer, an initial IM antibiotic followed by a course of oral antibiotics and direct wound care. The patient was instructed to elevate her right foot as much as possible. After initial debridement (including sharp), PolyMem Max dressings were applied directly to the wound and changed every-other-day. Later, the wound-care frequency was decreased to twice per week. Wound cleansing was not necessary after the first week. The left foot was soaked in a heavy salt solution to treat the fungal infection, but the injured right foot was not treated for the fungal infection until the wound was completely closed.

RESULTS

Pain was greatly reduced and the wound infection resolved within a week. The wound moisture became appropriate and granulation tissue formed quickly. The wound healed and the patient was able to return to her home in 9 weeks.

CONCLUSION

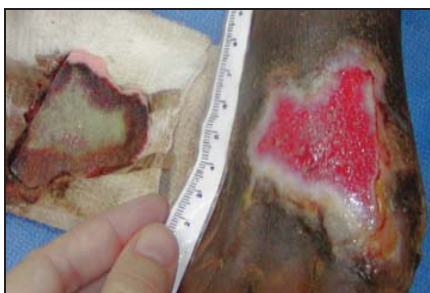
PolyMem Max dressings provided effective wound management for a full-thickness crush wound from initiation of treatment to complete wound closure. Use of the PolyMem Max dressings controlled pain and infection and completely eliminated the necessity of wound cleansing at dressing changes.

BIBLIOGRAPHY:

1. Beitz AJ, Newman A, Kahn AR, Ruggles T, Eikmeier L. A polymeric membrane dressing with antinociceptive properties: analysis with a rodent model of stab wound secondary hyperalgesia. *Journal of Pain*. 2004 Feb;5(1):38-47. 2. Worley CA. So, what do I put on this wound? Making sense of the wound dressing puzzle: Part II. *Dermatological Nursing* 2005;17(3):203-5. 3. Hess CT. *Wound Care Clinical Guide*. 5th ed. Ambler, PA: Lippincott Williams & Wilkins; 2005. p. 274. 4. Fowler E, Papen JC. Clinical evaluation of a polymeric membrane dressing in the treatment of dermal ulcers. *Ostomy Wound Management*. 1991;35:35-38,40-44. 5. Blackman JD, Senseng D, Quinn L, Mazzone T. Clinical evaluation of a semipermeable polymeric membrane dressing for the treatment of chronic diabetic foot ulcers. *Diabetes Care*. 1994;17(4):322-5. 6. Coppi C. I dressed your wounds, God healed you – a wounded person's psychology according to Ambrose Pare. *Ostomy Wound Management*. 2005 Aug; 51(8):62-4.

This case study was unsponsored. The clinic receives donated supplies from many sources, including Ferris Mfg. Corp., who contributed to the poster design. Gloves were in short supply when this patient was being treated.

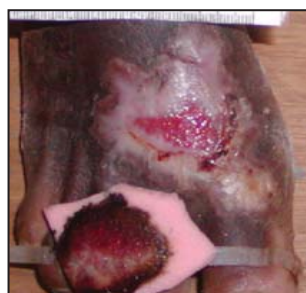
Linda Benskin, BSN, RN, SRN (Ghana), Church of Christ Mission Clinic, PO Box 137, Yendi, Northern Region, GHANA, West Africa



OCT 31

4.4 cm x 4.3 cm

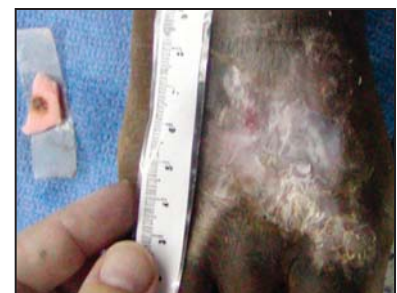
The wound bled during the patient's 6 mile walk to the clinic, but the dressing absorbed the exudate.



NOV 17

1.3 cm x 2 cm

Walking to the clinic only every 3 days now – wound is filling in.



DEC 8

The patient returned to her village after 9 weeks of treatment - Success.



Ferris Mfg. Corp.

16W300 83rd Street
Burr Ridge, Illinois 60527 USA
Phone: 1-800-POLYMEM, +1 630-887-9797
Email: info@FerrisPolyMem.com
Web site: www.PolyMem.com
www.PolyMem.eu

Presented at :

19th Annual Symposium on Advanced Wound Care (SAWC). Poster #32.
April 30 - May 3, 2006. San Antonio, TX USA

21st Annual Clinical Symposium on Advances in Skin & Wound Care. Poster #22.
September 28 - October 1, 2006. Orlando, FL USA

The WOCN Society's 39th Annual Conference. Poster #1248.
June 10 - 13, 2007. Salt Lake City, Utah USA

PolyMem, PolyMem Silver, PolyMem Wic, PolyMem Wic Silver, PolyMem Max, PolyMem Max Silver, Shapes, Shapes by PolyMem, QuadraFoam, The Shape of Healing, Ferris, and FMC Ferris and design are trademarks of Ferris. The marks may be registered or pending in the US Patent and Trademark Office and in other countries. © 2007 Ferris Mfg. Corp. All rights reserved.
MKL-284,REV-1,0508