

**CASE STUDY**

**Maintaining Tunnel Tissue Viability with  
PolyMem® Silver® QuadraFoam® Dressings  
During Osteomyelitis Treatment**



**Ferris Mfg. Corp.**

16W300 83rd Street  
Burr Ridge, Illinois 60527 USA  
Phone: 1-800-POLYMEM, +1 630-887-9797  
Email: info@FerrisPolyMem.com  
Web site: www.PolyMem.com  
www.PolyMem.eu

Presented at:

20th Clinical Symposium on Advances in Skin and Wound Care. Poster #97.  
October 23 - 26, 2005. Las Vegas, NV USA

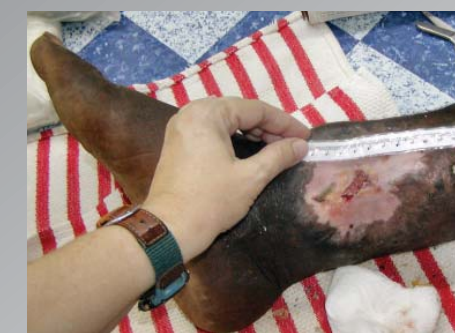19th Annual Symposium on Advanced Wound Care (SAWC). Poster #22.  
April 30 - May, 2006. San Antonio, TX USA

WOCN Society 38th Annual Conference. Poster #136/Abstract #1718.  
June 24 - 28, 2006. Minneapolis, MN USA

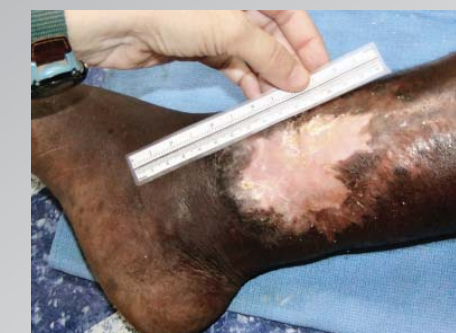3rd Congress of the World Union of Wound Healing Societies. Poster #PF438.  
June 4 - 8, 2008. Toronto, Ontario Canada

PolyMem, PolyMem Silver, PolyMem Wic, PolyMem Wic Silver, PolyMem Max, PolyMem Max Silver, Shapes, Shapes by PolyMem, QuadraFoam, The Shape of Healing, Ferris, and FMCFerris and design are trademarks of Ferris. The marks may be registered or pending in the US Patent and Trademark Office and in other countries. © 2008 Ferris Mfg. Corp. All rights reserved.

MKL-215,REV-4,1008



**BEFORE**



**AFTER**

## CASE STUDY

# Maintaining Tunnel Tissue Viability with PolyMem Silver QuadraFoam Dressings During Osteomyelitis Treatment

### PROBLEM

A 35-year-old farmer in Ghana, West Africa, arrived with a non-healing wound due to osteomyelitis secondary to an unset compound fracture. He broke his leg in a motor-vehicle-accident 10 months previous but left the hospital "against medical advice" to avoid amputation. The proximal right ankle wound was 2 cm long x 3 cm wide with an adjacent 2.5 cm deep tunnel extending to the bone. The exterior wound was self-treated with an amoxicillin powder (poured out of capsules) and petrolatum mixture. Weight-bearing on the deformed leg was painful. Relative humidity during treatment was often well below 10% and always below 30%, which made it difficult to maintain a moist wound-healing environment. Since surgery to remove the dead bone was not available, the tunnel needed to be kept open and viable until the dead bone particles were ejected.

### RATIONALE

PolyMem Silver dressings and PolyMem Wic® Silver cavity wound filler have demonstrated the ability to provide antimicrobial benefits in low humidity environments because of the residual moisture in the dressings and the natural hydrophilic action of the dressings. Both the PolyMem Silver dressing and the PolyMem Wic Silver filler contain evenly distributed nanocrystalline silver particles that provide additional antimicrobial benefits. The PolyMem Wic Silver filler provided a mechanical means to keep the tunnel, which served as a portal of exit for dead bone, open and appropriately moist until the osteomyelitis resolved.

### METHODOLOGY

Treatment included nutritional counseling, prayer and oral antibiotics in addition to direct wound care. PolyMem Wic Silver cavity wound filler was inserted into the tunneling wound. PolyMem dressings (with a semi-permeable film coating), with or without silver, were applied over the exterior wound.

### RESULTS

The infection was controlled quickly and dead bone fragments were removed from the base of the tunnel as they were released by the body. Walking became pain-free when the bone infection resolved. The tissue along the inner edges of the tunneling wound remained viable. The wound completely healed in 17 weeks and did not recur.

### CONCLUSION

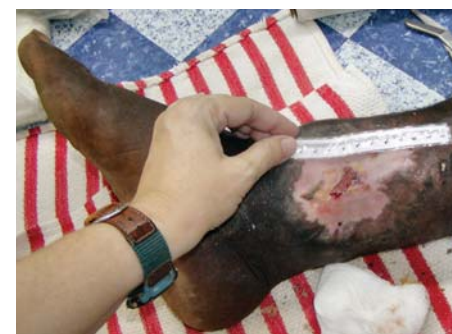
PolyMem Silver dressings and PolyMem Wic Silver cavity wound filler provided excellent results during the entire healing process to closure. The PolyMem Wic Silver filler kept the tissue along the inner edges of the tunneling wound viable for months, even in conditions of extremely low relative atmospheric humidity. The patient was able to continue farming throughout the treatment.

### TUNNELING WOUNDS

Although clinicians in developed areas rarely encounter osteomyelitis cases in which IV antibiotic treatment and surgery to remove dead bone are not options, tunneling wounds are recognized as being among the more difficult to treat. Tissue along the inner edges of the tunnel must be viable for healing to occur. The PolyMem Wic Silver cavity wound filler kept this tissue clean and moist so that as soon as all the dead bone was expelled by the patient's body, the tunnel could close.

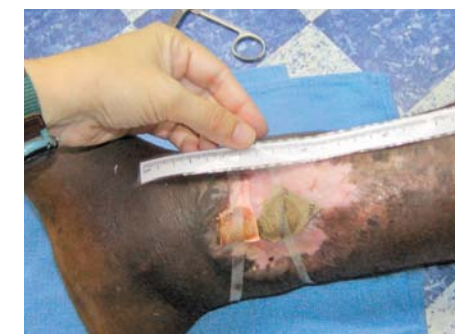### OBJECTIVES

1. Discuss problematic issues related to non-healing wounds resulting from acute trauma.
2. Consider the advantages in terms of maintaining tissue moisture to using PolyMem Wic Silver cavity wound filler instead of a large-bore drain in extremely dry conditions.
3. Show that PolyMem QuadraFoam dressings and cavity wound filler, categorized in the United States as foam dressings, have a wider treatment range of applicability than is generally recognized for dressings in the "foam" category.
4. Demonstrate that PolyMem Silver dressings and PolyMem Wic Silver cavity wound filler can be initiated at any stage of healing and can be used to complete closure.



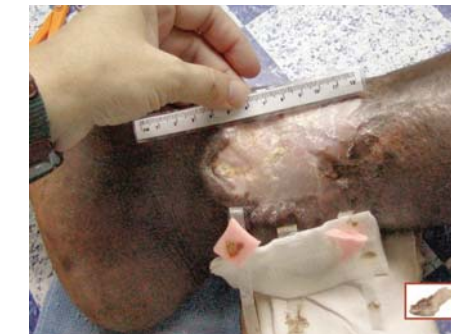
**Nov 18**

Treatment initiated with PolyMem Wic Silver filler inserted into the 2.5 cm deep tunnel to infected bone to keep it open, clean and moist. Entire open area covered with PolyMem dressings.



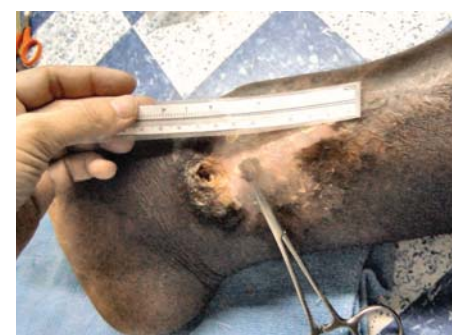**Nov 21**

Dressing appearance prior to its removal. Exterior wound and tunnel both staying clean and moist despite patient's long hours on hands and knees working his arid, dusty farm.



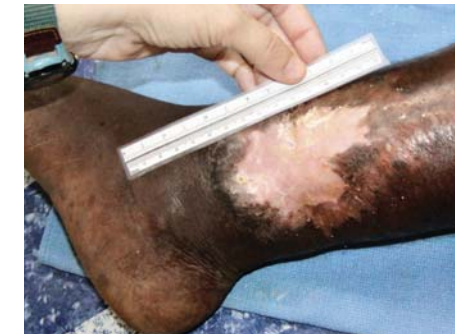**Jan 19**

One week previous, 0.9 cm long bone shard (inset) removed; more dead bone remains. Exterior wound healed. Tunnel exudate minimal and less foul. Therefore, using standard PolyMem dressings instead of silver.



**Feb 23**

Last dead bone fragment removed a few days earlier. The osteomyelitis is resolved; the tunnel is free of dead bone and without drainage, but moist and viable, so it is finally allowed to fill in from the bottom up.



**March 18**

Tunnel filled in fully. Despite the permanent deformity and fore-shortening of his leg, the patient is able to walk well without pain. Successful dismissal.

**Linda Benskin, RN, BSN, Ghana, SRN,  
Church of Christ Mission Clinic, P.O. Box  
137, Yendi, Northern Region, GHANA,  
West Africa**

This case study was unsponsored. The clinic receives donated supplies from many sources, including Ferris Mfg. Corp., who contributed to this poster design.

### BIBLIOGRAPHY:

1. Cutting KF, White RJ. Criteria for identifying wound infection-revisited. *Ostomy Wound Management*. 2005;51(1):28-34.
2. Driver VR. Silver dressings in clinical practice. *Ostomy Wound Management*. 2004 Sept;50(9A Supplement):115-155.
3. Hess CT. *Wound Care Clinical Guide*. 5th ed. Ambler, PA: Lippincott Williams & Wilkins; 2005.
4. Lansdown ABG. Silver I: Its antimicrobial properties and action. *Journal of Wound Care*. 2002 April;11(4):125-130.
5. Ovington LG. The truth about silver. *Ostomy Wound Management*. 2004 Sept;50(9A Supplement):15-105.
6. Rolstad BS, Ovington LG, Harris A. Principles of Wound Management. In: *Acute and Chronic Wounds Nursing Management*. Bryant RA, editor. 2nd ed. St. Louis: Mosby; 2000. p.85-124.
7. Coppi C. I dressed your wounds, God healed you – a wounded person's psychology according to Ambrose Pare. *Ostomy Wound Management*. 2005 Aug;51(8):62-4.