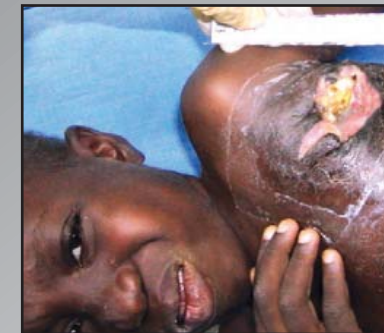
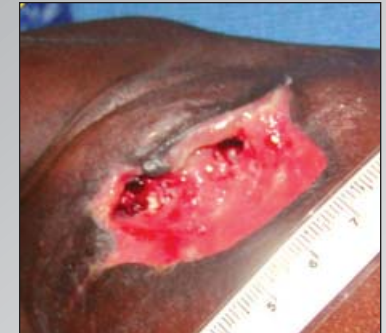
CASE STUDY

Dramatic Pain Relief Through the Use of PolyMem® QuadraFoam® Dressings on a Deep Axillary Wound for Entire Course of Healing



SEVERE PAIN



PAIN RELIEF



Ferris Mfg. Corp.

16W300 83rd Street
Burr Ridge, Illinois 60527 USA
Phone: 1-800-POLYMEM, +1 630-887-9797
Email: info@FerrisPolyMem.com
Web site: www.PolyMem.com
www.PolyMem.eu

Presented at :

20th Clinical Symposium on Advances in Skin and Wound Care. Poster #96.
October 23 - 26, 2005. Las Vegas, NV, USA

19th Annual Symposium on Advanced Wound Care (SAWC). Poster #25.
April 30 - May 3, 2006. San Antonio, TX, USA

WOCN Society 38th Annual Conference. Poster #167/Abstract #1686.
June 24 - 28, 2006. Minneapolis, MN, USA

3rd Congress of the World Union of Wound Healing Societies. Poster #PF413.
June 4 - 8, 2008. Toronto, Ontario Canada

PolyMem, PolyMem Silver, PolyMem Wic, PolyMem Wic Silver, PolyMem Max, PolyMem Max Silver, Shapes, Shapes by PolyMem, QuadraFoam, The Shape of Healing, Ferris, and FMC Ferris and design are trademarks of Ferris. The marks may be registered or pending in the US Patent and Trademark Office and in other countries. © 2008 Ferris Mfg. Corp. All rights reserved.

Dramatic Pain Relief Through the Use of PolyMem QuadraFoam Dressings on a Deep Axillary Wound for Entire Course of Healing

PROBLEM

A severely malnourished (15 kg) six-year-old girl in Ghana, West Africa, with undiagnosed axillary lymphatic tuberculosis for over three months came to the clinic for malaria treatment. The wound from a partial surgical excision at another facility two weeks prior was irregularly-shaped, 4 cm x 4 cm x 6 cm deep, lightly exudating, malodorous, continuously painful, and surrounded by inflammation and erythema (Figure 1). The patient had been dismissed with 3% hydrogen peroxide for cleansing and oral antibiotics. The clinic transferred the patient to the hospital for surgical debridement, but the patient was dismissed after two days, having had no direct wound care (Figure 2).

RATIONALE

Family skepticism about “modern” medical treatment for the abscess plus the patient’s severe wound pain made immediate results critical (Figures 3 and 5). The clinic’s other wound patients reported dramatic pain relief when treated with PolyMem QuadraFoam dressings. PolyMem dressings have demonstrated ability to reduce inflammation, as well. Polymem Silver® dressings and PolyMem Wic® Silver cavity wound filler provide antimicrobial benefits. Therefore, PolyMem Silver dressings were initiated.

METHODOLOGY

After sharp debridement at clinic, patient treatment focused on decreasing pain and infection through use of PolyMem Silver dressings, PolyMem Wic Silver cavity wound filler (Figure 4) and oral antibiotics, while improving the patient’s health through nutrition and prayer. Due to local conditions, TB treatment had to be delayed until the wound was fully healed. The wound was managed with various PolyMem dressings from treatment initiation to complete closure, based on the wound’s condition (Figure 6). Initially, the wound was lightly filled with PolyMem Wic Silver cavity wound filler. PolyMem Wic Silver conformed fully to wound’s irregular shape and easily filled tunneling (Figure 4).

RESULTS

Treatment with PolyMem dressings eliminated wound pain completely within 24 hours. Wound odor quickly diminished as well. Initial hospital lab results falsely indicated that there was no TB. Therefore, infected lymph tissue was removed periodically (Figure 5). This was, of course, painful. But, despite the patient’s severe malnutrition, recent malaria and active tuberculosis, the wound completely closed in 16 weeks (Figure 7).

CONCLUSION

Treatment with the PolyMem family of dressings provided effective wound management from the initiation of treatment to complete wound closure. Patient’s presenting at this clinic with a variety of wounds report dramatic pain relief when treated with PolyMem dressings. In addition, PolyMem Silver membrane dressings effectively addressed wound inflammation and infection.

ADDITIONAL FINDING

After a trial with PolyMem family of dressings, many chronic wound care patients in this care setting refused to allow the caregivers to change their treatment to another dressing type, claiming that the PolyMem dressings provided dramatic pain relief. Through the use of PolyMem dressings this particular patient quickly became pain-free except during dressing changes involving aggressive mechanical debridement, even in this sensitive area of the body.

OBJECTIVES

1. Discuss problematic issues related to dressing a painful axillary abscess wound.
2. Consider the use of flexible PolyMem Silver dressings and PolyMem Wic cavity wound fillers when there is a need to decrease inflammation and infection while minimizing pain.
3. Show that PolyMem QuadraFoam dressings, categorized in the United States as foam dressings, have a wider treatment range of applicability than is generally recognized for dressings in the “foam” category.
4. Demonstrate that use of the PolyMem family of dressings and fillers can be initiated at any stage of healing and that these dressings are beneficial to complete closure.

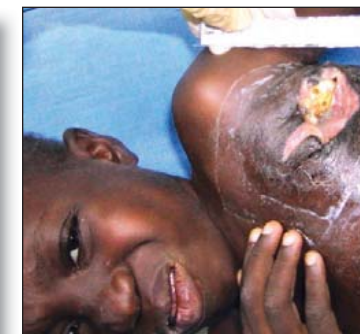

Figure 1
Nov 19 - Initial assessment (Severe Pain)

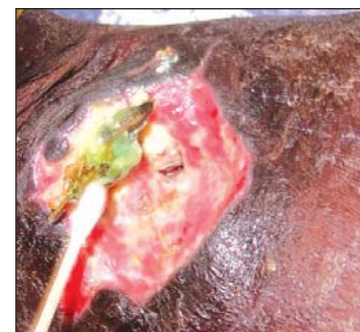


Figure 2
Nov 21 - Prior to sharp debridement.

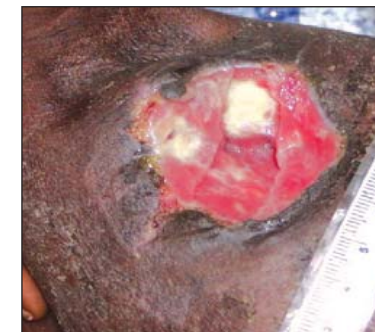

Figure 3
Nov 25 - Already granulating, but lymph TB is rapidly regrowing in the wound bed.

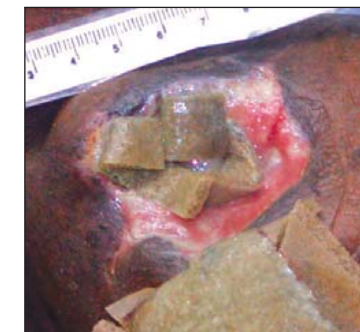

Figure 4
Dec 1 - The dressings could be cut to fill dead space in virtually any shape. (Pain Relief)

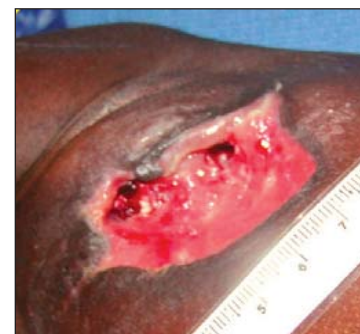

Figure 5
Dec 4 - The TB-infected lymph tissue was repeatedly removed, leaving deep holes; PolyMem Wic Silver provided effective pain relief.

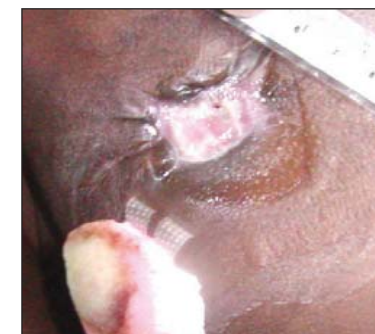

Figure 6
Jan 17 - Healing well. No surface infection or inflammation, so silver dressings are not needed.

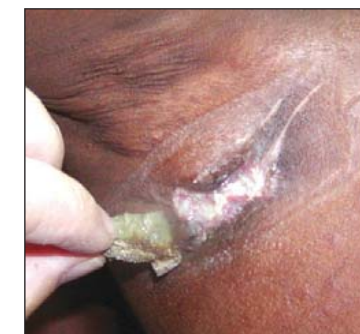

Figure 7
Feb 20 - Complete closure is imminent; transportation to TB treatment facility arranged.

Linda Benskin, RN, BSN, Ghana SRN, Church of Christ Mission Clinic, P.O. Box 137, Yendi, Northern Region, GHANA, West Africa

This case study was unsponsored. The clinic receives donated supplies from many sources, including Ferris Mfg. Corp., who contributed to this poster design.

BIBLIOGRAPHY:

1. Cutting KF, White RJ. Criteria for identifying wound infection-revisited. *Ostomy Wound Management*. 2005;51(1):28-34.
2. Hess CT. *Wound Care Clinical Guide*. 5th ed. Ambler, PA: Lippincott Williams & Wilkins; 2005.
3. Keen D, James J. A tool to aid nurses’ decision making in relation to dressing selection. *British Journal of Nursing*. 2004 Aug 12; 13(15 Supplement):S6 - S14.
4. Lansdown ABG. Silver I: Its antimicrobial properties and action. *Journal of Wound Care*. 2002 April;11(4):125-130.
5. Ovington LG. The truth about silver. *Ostomy Wound Management*. 2004 Sept;50(9A Supplement):15-105.
6. Rolstad BS, Ovington LG, Harris A. Wound Care Product Formulary. In *Acute and Chronic Wounds Nursing Management*. Bryant RA, editor. 2nd ed. St. Louis: Mosby; 2000. p.113-124.
7. Coppi C. I dressed your wounds, God healed you – a wounded person’s psychology according to Ambrose Pare. *Ostomy Wound Management*. 2005 Aug; 51(8):62-4.